

---

# Youngest netherton patient with infantile asthma

Ebru KÜTSAL<sup>1</sup>, Kıvılcım GÜCÜYENER<sup>2</sup>, Arzu BAKIRTAŞ<sup>2</sup>, Nilüfer ELDEŞ<sup>1</sup>, Murat ÖZTAŞ<sup>3</sup>, Ayşe DÜRSÜN<sup>4</sup>

<sup>1</sup> Zonguldak Karaelmas Üniversitesi Tıp Fakültesi, Çocuk Sağlığı ve Hastalıkları Anabilim Dalı, Zonguldak,

<sup>2</sup> Gazi Üniversitesi Tıp Fakültesi, Çocuk Sağlığı ve Hastalıkları Anabilim Dalı,

<sup>3</sup> Gazi Üniversitesi Tıp Fakültesi, Dermatoloji Anabilim Dalı,

<sup>4</sup> Gazi Üniversitesi Tıp Fakültesi, Patoloji Anabilim Dalı, Ankara.

## ÖZET

### *İnfanıl astımı olan en küçük netherton hastası*

*Netherton sendromu iktiyozis, atopi, bambu saç ve aralıklı aminoasidüri ile karakterize bir sendromdur. Yenidoğan ve küçük bebeklerde eritrodermi belirgin olup, netherton sendromuna ait diğer klinik ve histopatolojik bulgulara az rastlanır. Ciddi solunum sıkıntısı, yaygın eritrodermisi, kırılğan saçları ve erken dönemde infanıl astım klinik bulgularıyla karşımıza çıkan altı aylık kız hastayı bildirmeyi gerekli gördük.*

**Anahtar Kelimeler:** *Netherton sendromu, bambu saç, aralıklı aminoasidüri, infanıl astım.*

## SUMMARY

### *Youngest netherton patient with infantile asthma*

Ebru KÜTSAL<sup>1</sup>, Kıvılcım GÜCÜYENER<sup>2</sup>, Arzu BAKIRTAŞ<sup>2</sup>, Nilüfer ELDEŞ<sup>1</sup>, Murat ÖZTAŞ<sup>3</sup>, Ayşe DÜRSÜN<sup>4</sup>

<sup>1</sup> Department of Children's Health and Diseases, Faculty of Medicine, Zonguldak Karaelmas University, Zonguldak, Turkey,

<sup>2</sup> Department of Children's Health and Diseases, Faculty of Medicine, Gazi University, Ankara, Turkey,

<sup>3</sup> Department of Dermatology, Faculty of Medicine, Gazi University, Ankara, Turkey,

<sup>4</sup> Department of Pathology, Faculty of Medicine, Gazi University, Ankara, Turkey.

---

## Yazışma Adresi (Address for Correspondence):

Dr. Ebru KÜTSAL, Zonguldak Karaelmas Üniversitesi Tıp Fakültesi, Çocuk Sağlığı ve Hastalıkları Anabilim Dalı,  
ZONGULDAK - TÜRKİY

e-mail: ebkut@yahoo.com

*Netherton syndrome is a very rare disorder characterized with ichthyosis, atopy, bamboo hair and intermittent aminoaciduria. The specificity of clinical and histopathological features of netherton syndrome is low in neonates and young infants who presents with predominating erythrodermia. Being the youngest infant presenting with the symptoms of infantile asthma we found it worth to report a six months old girl presenting with the feature of severe respiratory distress, generalized erythrodermia, and brittle hair.*

**Key Words:** *Netherton syndrome, bamboo hair, intermittent aminoaciduria, infantile asthma.*

Netherton syndrome is a rare, autosomal recessive disorder characterized by ichthyosis, hair shaft abnormalities and atopic diathesis (1,2). The first presenting symptom may be congenital erythrodermia and later on development of ichthyosis linearis circumflexa may occur (1-3). The hair abnormalities encompasses trichorrhexis invaginata, pilli torti and trichorrhexis nodosa (1,4,5). In terms of atopy the co-existence of asthma, allergic rhinitis, angioneurotic edema, and anaphylactoid reactions, elevated serum IgE levels are frequently defined (2,3). Other features of the syndrome include also immune abnormalities, failure to thrive, enteropathy, cardiac, gastrointestinal, uriner malformations and intermittent aminoaciduria (1,2,4,6). Genetically it is localized to chromosome 5q32 and several mutations in SPINK 5 gene encoding the serine protease inhibitor were found (7,8). The specificity of clinical and histopathological features of netherton syndrome is low in neonates and young infants who presents with predominating erythrodermia. Being the youngest infant presenting with the symptoms of infantile asthma we found it worth to report a six months old girl presenting with the feature of severe respiratory distress, generalized erythrodermia, and brittle hair.

### CASE REPORT

A six month old girl admitted to the emergency department with severe respiratory insufficiency, generalized erythrodermia and ichthyosis. On admission to the hospital, she had persistent wheezing for about three weeks. She was born with ichthyosis at the 38 week of gestation after an uneventful pregnancy by cesarean section to healthy consanguineous patients. Her two sisters aged five and nine years of age were in good health and relatives had no history of atopy. On the

second week of her life, she developed generalized erythematous scaling skin. In the history it's learned that she was hospitalised because of wheezing at second and fourth months of her life and in first hospitalisation a probable diagnosis of Leiner's disease was made because of severe hypernatremic dehydration and gastroenteritis. Physical examination revealed an irritable child with a height of 56 cm below 3<sup>rd</sup> percentile and weight of 4100 g below 3<sup>rd</sup> percentile. There were erythematous scaly lesions on all over the body and scalp. The scalp hair was dry, scarce and brittle especially short in the temporal and occipital regions (Figure 1). She had severe tachypnea, tachycardia and generalized wheezing with crackles in both two lungs. The rest of the physical examination were normal. Laboratory investigations of complete blood count, routine biochemical tests, trace elements (serum copper and zinc levels) were within normal limits. Serum levels of IgG, IgA, IgM, IgE and IgG subclasses (IgG1, IgG2, IgG3, IgG4) and complement C3, C4 and C5 levels were also all in normal limits. Her tidal breathing lung function test were done under sedation (chloralhydrate 50 mg/kg per oral) revealed no fixed obstruction and was consistent with intrathoracic obstruction on tidal flow-volume loop (Figure 2). Asthma was diagnosed by persistent wheezing which showed a favourable response to the anti-asthma medication and she was put on salbutamol 0.15 mg/kg/dose 6 times a day and inhaled budesonide therapy of 2000 µg/day. When the blood culture was positive for *Staphylococcus coagulase* (positive) species, vancomycine was started 40 mg/kg/day for 10 days until a negative blood culture was available. On the 3<sup>rd</sup> day of her admission she was found to have generalized aminoaciduria, which led us to examine her scalp hair. Light microscop-

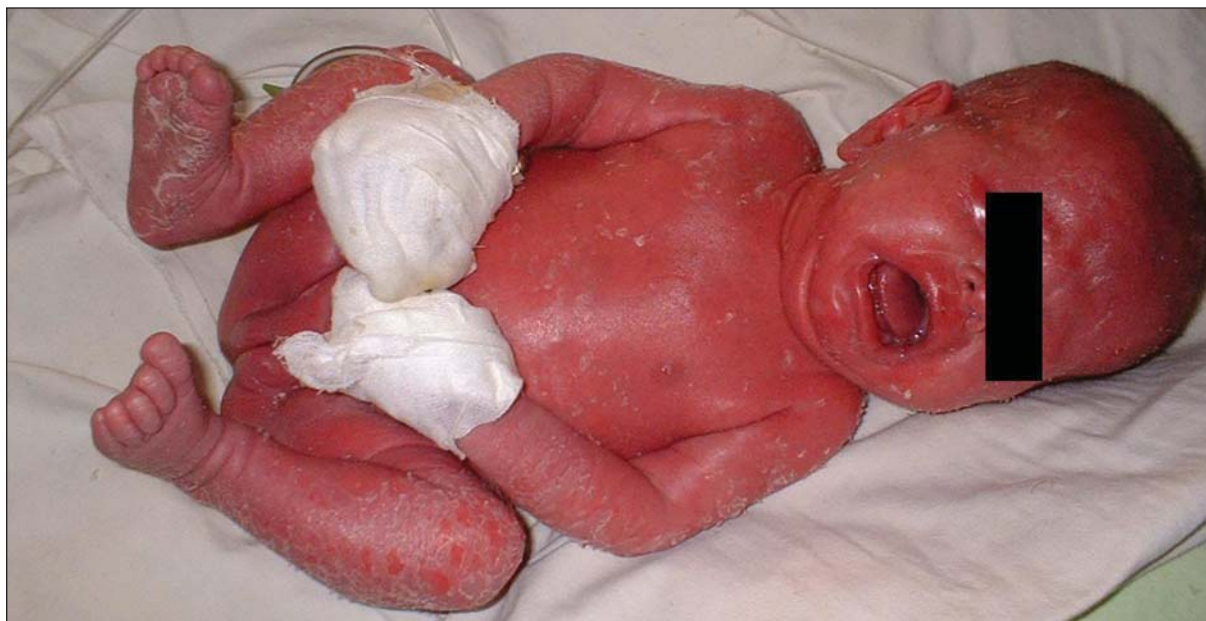

Figure 1. Erythematous scaly lesions on all over the body and scalp, her scalp hair was dry scarce and brittle especially short in the temporal and occipital regions.

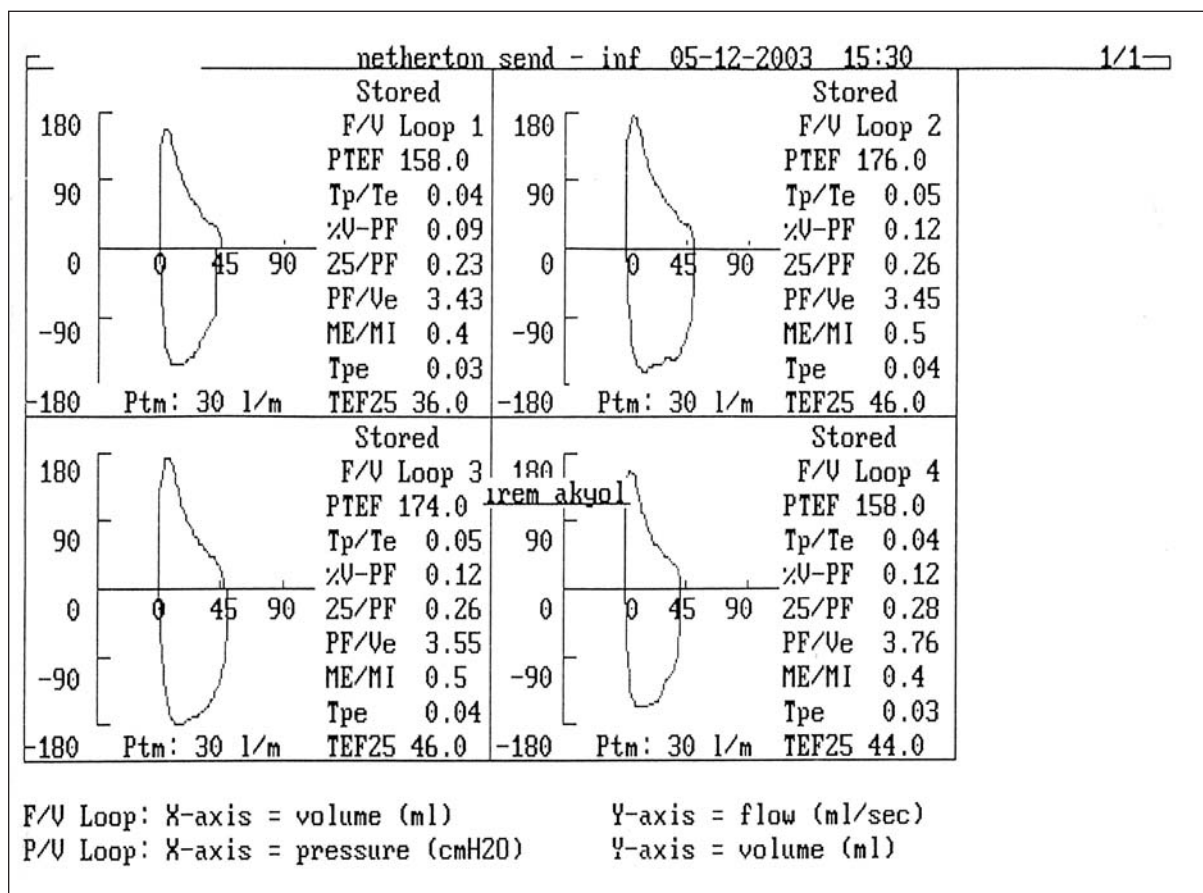


Figure 2. Pulmonary function tests, revealing no fixed obstruction and consistent with intrathoracic obstruction on tidal flow-volume loop.

pic examination showed typical bamboo deformity of trichorrhexis invaginata and discrete total twisting of the hair shaft. Lipid vacuoles in keratin layer was revealed at the electron microscopy of her skin biopsy which is the indicative of netherton syndrome.

To rule out the co-existing abnormalities Doppler echocardiogram, Denver developmental screening test and abdominal ultrasonography done were all normal. After the asthma symptoms regressed, inhaled steroid therapy was ceased and the aminoaciduria disappeared.

### DISCUSSION

Netherton syndrome is a rare autosomal recessive disease consisting mainly of ichthyosis linearis circumflexa, trichorrhexis invaginata and/or pili torti and atopy prone state (1,2,4). Before two years of age the children with netherton syndrome develop congenital generalized erythrodermia which is evident at birth or during first weeks of life, with varying severity (1,3). Metabolic diseases, immunodeficiency, acrodermatitis enteropatica, atopic dermatitis, seborrheic dermatitis, psoriasis can all be the cause of erythrodermia and sometimes the exact reason remains unknown. Furthermore, erythrodermic infants and neonates are at great risk to get hypernatremic dehydration, sepsis, malnutrition and failure to thrive as it happened in our case. During the 2<sup>nd</sup> year, the classical erythrodermia disappears and ichthyosis linearis circumflexa which is characterized by a generalized desquamative annular plaque with a double edge scale becomes the predominant skin lesion in netherton patients (1,3). One of the main symptom triad is the trichorrhexis invaginata in which the distal hair segment is telescoped into the proximal one, forming a ball and socket like deformities on microscopic examination, another name given is bamboo-hair. To find out this abnormalities hair from multiple areas should be examined because only 20-50% of hair may be affected. Our patient is also very interesting for having this abnormality in a very young age, when the percentage of presentation is expected to be even lower.

In terms of atopy, patients with netherton syndrome may present with allergic rhinitis, angioedema, asthma, urticaria, anaphylaxis, elevated IgE levels and family history of atopic disease (3,4). Our patient had also developed severe infantile asthma at the age of six months with normal IgE levels and without atopy history in family. The diagnosis of infantile asthma was made with recurrent wheezing attack 3 times in her history, physical examination and tidal breath function test which revealed no fixed obstruction and intrathoracic obstruction on tidal flow-volume loop. To the best of our knowledge from the patients in the literature, our case is the youngest netherton patient presenting with infantile asthma so far (9,10). Recurrent infections can also be a disturbing feature of patients with netherton syndrome especially at younger ages. Apart from skin infections, upper and lower respiratory tract, infections may occur. Our patient also had skin originated systemic infection of *Staphylococcus coagulase* (positive) species which is treated with vancomycine therapy. Intermittent iatrogenic aminoaciduria had been defined in patients with netherton syndrome who were being treated either by topical or systemic corticosteroids without any renal insufficiency (1,5,6,11). The steroid absorption in these patients is explained via an impaired mucosal or skin barrier defect. The renal function tests of our patient was also normal. Although topical or systemic steroids were not used in our patient, the dose of inhaled budenoside (2000 µg/day) was high enough to cause systemic effect which may explain the transient aminoaciduria reversed after cessation of inhaled steroid treatment. Therefore her intermittant aminoaciduria can only be explained due to the inhaled steroid therapy if it is not a feature of the syndrome. The therapy of patients with netherton syndrome includes emmollients, topical steroids, PUVA and oral vitamine A and tacrolimus, with various success (8,12,13). We had used topical emollients with good result.

The specificity of clinical and histopathological feature of netherton syndrome is low in neonates and the characteristic changes (trichorrhexis invaginata and ichthyosis linearis circumflexa) usu-

ally do not occur before the age of two years. It is a great challenge to make the correct diagnosis without having those patients to get the wrong diagnosis of non-bullous congenital ichthyosiform erythrodermia (NBCIE), atopic dermatitis or Leiner's disease. Netherton syndrome should be on top of the differential diagnosis list in a newborn child with erythrodermia and abnormal looking scalp hair. Furthermore if this child has the symptoms of atopy and respiratory distress, every effort should be given to rule out infantile asthma in order to get appropriate diagnosis and intervention as early as possible, to provide the child a good life quality.

#### REFERENCES

1. Greene SL, Muller SA. Netherton's syndrome report of a case and review of the literature. *J Am Acad Dermatol* 1985; 13: 329-37.
2. Julius CE, Keeran M. Netherton's syndrome in a male. *Arch Dermatol* 1971; 104: 422-4.
3. Judge MR, Morgan G, Harper JL. A clinical and immunological study of netherton syndrome. *Br J Dermatology* 1994; 131: 615-21.
4. Yerebakan Ö, Uğuz A, Keser İ, et al. Netherton syndrome associated with idiopathic congenital hemihypertrophy. *Ped Dermatol* 2002; 19: 345-8.
5. Plantin P, Delaire P, Guillet MH, et al. Netherton syndrome. Current aspects. A propose of 9 cases. *Ann Dermatol Venereol* 1991; 118: 525-30.
6. Smith DL, Smith JG, Wong SW, Shazo RD. Netherton's syndrome: A syndrome of elevated IgE and characteristic skin and hair findings. *J Allergy Clin Immunol* 1995; 95: 116-23.
7. Chavanas S, Bodemer C, Rochat A, et al. Mutations in SPINK 5, encoding a serine protease inhibitor, cause netherton syndrome. *Nat Genet* 2000; 25: 141-2.
8. Chavanas S, Garner C, Bodemer C, et al. Localization of the netherton syndrome gene to chromosome 5q32, by linkage analysis and homozygosity mapping. *Am J Hum Genet* 2000; 66: 914-21.
9. Dragos V, Godic A. Netherton syndrome. *Acta Dermatol Venerologica* 2000; 9: 2.
10. Arslanagic N, Arslanagic R. Netherton syndrome with recurrent herpes of facial skin. *Med Arc* 2002; 56: 221-4.
11. Caputo R, Vanutti P, Bertani E. Netherton's syndrome in two adult brothers. *Arch Dermatol* 1984; 120: 220-2.
12. Hartschuh W, Hausser I, Petzoldt D. Successful retinoid therapy of netherton syndrome. *Hautarzt* 1989; 40: 430-3.
13. Happle R, van de Kerkhof PC, Traupe H. Retinoids in disorders of keratinization: Their use in adults. *Dermatologica* 1987; 175(Suppl 1): 107-24.