
A rare cause of persistent atelectasis in childhood: Mucoepidermoid carcinoma

Ayhan SÖĞÜT, Özge YILMAZ, Hasan YÜKSEL

Celal Bayar Üniversitesi Tıp Fakültesi, Çocuk Sağlığı ve Hastalıkları Anabilim Dalı, Çocuk Allerji Bilim Dalı ve Solunum Birimi, Manisa.

ÖZET

Çocukluk çağında persiste eden atelektazinin nadir bir nedeni: Mukoepidermoid karsinom

On iki yaşındaki erkek hasta wheezing, öksürük ve bronkopnömoni şeklinde tekrarlayan alt solunum yolu yakınmaları ve düşmeyen ateş nedeniyle bakteriyel endokardit ön tanısıyla kliniğimize başvurdu. Fizik muayenesinde solunum sesleri sol alt zonda azalmıştı. Kalp sesleri ve ekokardiyografisi normal olarak saptandığı için bakteriyel endokardit ekarte edildi. Akciğer grafisi ve bilgisayarlı tomografisinde sol alt lobda konsolidasyon ve atelektazik görünüm vardı. Uygun antibiyoterapi, bronkodilatör tedavi ve postüral drenaja rağmen atelektazik görünüm persiste etti. Fiberoptik fleksibl bronkoskopi (FFB) ile sol alt lob bronşunu tamamen tıkayan tümöral kitle saptandı. Açık akciğer biyopsi materyalinin patolojik incelemesinde düşük dereceli mukoepidermoid karsinoma tanısı kondu. Olguya sol alt lobektomi uygulandı. Hasta operasyondan 12 ay sonra iyi idi. Yineleyen alt solunum yolu semptomları, persiste eden atelektazisi ya da fokal infiltratif görünümü olan hastalarda erken dönemde FFB yapılması uygun olacaktır.

Anahtar Kelimeler: Atelektazi, çocukluk çağı, akciğer, mukoepidermoid tümör.

SUMMARY

A rare cause of persistent atelectasis in childhood: Mucoepidermoid carcinoma

Ayhan SÖĞÜT, Özge YILMAZ, Hasan YÜKSEL

Division of Pediatric Allergy and Pulmonology Unit, Department of Children's Health and Diseases, Faculty of Medicine, Celal Bayar University, Manisa, Turkey.

Yazışma Adresi (Address for Correspondence):

Dr. Ayhan SÖĞÜT, Celal Bayar Üniversitesi Tıp Fakültesi, Çocuk Sağlığı ve Hastalıkları Anabilim Dalı, Çocuk Allerji Bilim Dalı ve Solunum Birimi, 45020 MANİSA - TÜRKİYE

e-mail: ayhansogut29@yahoo.com

A 12-year-old boy presented to our clinic with recurrent lower respiratory tract symptoms that are wheezing, cough, bronchopneumonia, and fever and with a diagnosis of bacterial endocarditis. Physical examination revealed that breath sounds diminished in the left lower lobe. Because cardiac sounds and echocardiography were normal bacterial endocarditis was excluded. Chest radiograph and computerized tomography scan showed a left lower lobe atelectasis and consolidation. Despite medical therapy including antibiotics, bronchodilator etc, atelectasis persisted. Fiberoptic flexible bronchoscopy (FFB) revealed a tumor that totally obstructed the left lower lobe bronchus. Open lung biopsy revealed a low-grade mucoepidermoid carcinoma. Left lower lung lobectomy was performed. The patient is in good condition 12 months after the operation. We proposed that FFB should be performed earlier in patients with recurrent lower respiratory symptoms who have persistent atelectasis or unifocal infiltration.

Key Words: Atelectasis, childhood, lung, mucoepidermoid tumor.

Mucoepidermoid carcinoma (MEC) of the tracheobronchial tree is a rare airway tumor. In cases that the tumor can be totally excised, prognosis is excellent and histologic features are of the "low-grade" variant. Delay in diagnosis may lead to local and distant spread and permanent lung damage. MEC of the lung was first described by Smetana in 1952 (1). MEC of the tracheobronchial tree is rare, accounting for only 0.1%-0.2% of the primary lung malignancies (2,3). Pathologic chest radiographic findings are common including lobar infiltrates, atelectasis or bronchiectasis (4).

We report a 12-year-old boy with bronchial MEC that was sent with the presumptive diagnosis of bacterial endocarditis, recurrent lower respiratory tract infections, asthma like symptoms and persistent atelectasis on the radiologic examination

CASE REPORT

Twelve year old boy was admitted to our clinic with fever, tachycardia, wheezing and cough for one week. He had history of recurrent lower respiratory tract symptoms such as wheezing, bronchopneumonia, cough and fever. Physical examination revealed fever of 39°C and diminished breath sounds in the left lower lobe. Examination of the other systems were normal. Bacterial endocarditis was excluded upon normal cardiac examination and echocardiography. Laboratory tests revealed white blood cell count of 25.900/mm³, hemoglobin of 11.1 g/dL, platelet count of 344.000/mm³. Blood smear demonstrated 80% neutrophils and 20% lymphocytes.

Erithrocyte sedimentation rate was 40 mm/hour. Blood culture and protein purified derivate (PPD) test was negative. Chest radiograph and computerized tomography (CT) scan showed left lower lobe atelectasis and consolidation (Figure 1). Antibiotherapy (cefuroxime sodium 100 mg/kg/day), nebulized bronchodilator (salbutamol) and postural drainage was initiated. Clinical and radiological findings persisted despite 15 days of therapy. Therefore, fiberoptic flexible bronchoscopy (FFB) was performed and revealed a tumor that totally obstructed the left lower lobe bronchus. Histopathologic examination of the open lung biopsy specimen taken via lateral thoracotomy demonstrated low-grade MEC (Figure 2). Subsequently the patient underwent a left thoracotomy with lower lobectomy. Histopathologic examination of the tumor removed during surgery did not disclose additional findings. It has been 12 months after surgery and the patient is free of disease.

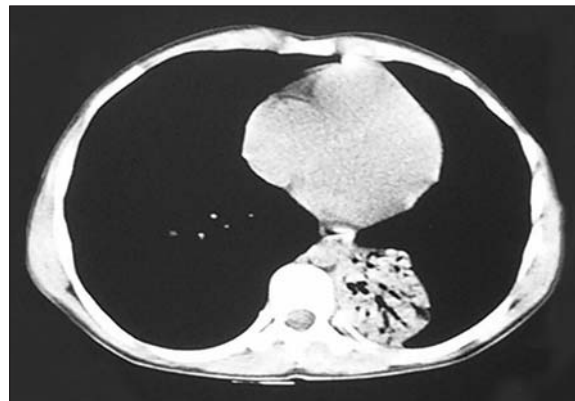


Figure 1. Computed tomography of the lung showing left lower lobe atelectasis and consolidation.

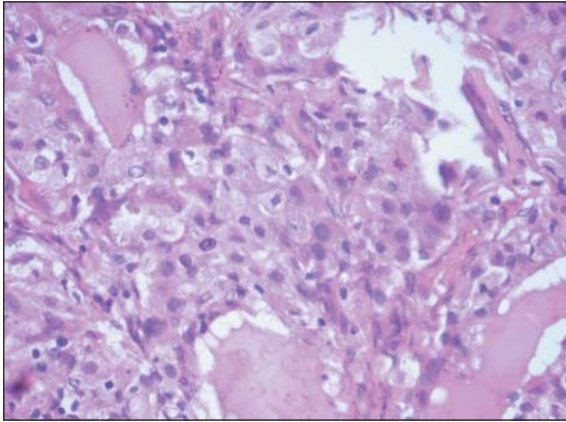


Figure 2. Tumor is composed of squamous, mucous and intermediate cells (HE, x200).

DISCUSSION

MEC of lung is a rare tumor (5). Patients vary in age from 3 months to 78 years but it is more commonly encountered in adults (6). It is believed to arise from excretory ducts of submucosal bronchial glands with a common origin of the salivary glands (6). The etiology in infants and children is not known (7).

A review of the literature indicates that 54 cases of bronchial MEC in children have been reported. Symptoms result from associated bronchial obstruction. Most common clinical signs include recurrent pneumonia or atelectasis. Common site of localization is the left or right lobar bronchi. Findings of the chest radiographs and CT scan include pneumonic infiltrates and atelectasis of the involved lobe, but diagnosis is established on bronchoscopy and biopsy findings. Histologic grade of MEC was low grade in most of the reported cases except one with high and two with intermediate grade without metastasis (8).

Symptoms of MEC are frequently due to bronchial obstruction with persistent cough, dyspnea, hemoptysis, wheezing and recurrent pneumonia (4). Some younger children may be misdiagnosed as new-onset asthma (9). MEC localized to left main bronchus was diagnosed in a 13 year old child by FFB evaluation of 169 children by Kut et al., between 1997 and 2000. The case had presented with recurrent pneumonia (10). Another case of tracheal MEC, reported by Oz et al., had presented with hemoptysis, dyspnea

and stridor (11). Our patient history revealed recurrent lower respiratory tract infections and symptoms suggestive of asthma.

Chest radiographic findings of bronchial MEC include recurrent or lobar infiltrates, atelectasis or bronchiectasis due to partial or complete endobronchial obstruction. In their research about radiological manifestations of tracheobronchial MEC, Yousem and Hochholzer reported that among the 58 cases in their group, 41 had a solitary nodule or mass (71%), 16 had pneumonic consolidation (28%) while one had no abnormality on chest radiograph (12). Moreover, in the research performed by Kim et al. on 12 cases, the prevalence of postobstructive pneumonia or atelectasis was 33% on chest radiogram. On CT imaging the tumours are central, smoothly oval or lobulated, homogeneous, may contain calcification and may show mild contrast enhancement (2). In the MEC case reported by Kut et al. CT has demonstrated left lower lobe atelectasis (13). Chest radiogram of our case demonstrated retrocardiac atelectasis in left lung and CT revealed persistent lower lobe atelectasis in the left lung.

MEC of the lung manifests as a polypoid mass in the lumen of a main, lobar, or segmental bronchus. With bronchoscopic examination tumor usually shows a partial or complete occlusion of the main stem bronchus by a lobulated gray or pink mass which is firm to touch but bleeds readily. While performing bronchoscopy, awareness of superadded infection over an endobronchial growth is important (13). FFB examination and biopsy are helpful in determining the cause of the respiratory symptoms and also unexpected lesions (14). Bronchoscopic examination can prevent delay in diagnosis. Diagnostic bronchoscopy in our patient revealed polypoid tumoral mass with a tendency to bleed at the entrance of left lower lobe bronchus.

Histologically, MECs are classified as low-grade to high-grade carcinomas (15). It is known that low-grade MECs grow slowly and are noninvasive and therefore rarely metastasize to regional lymph nodes or remote sites (12,16,17). In one study (12), only 2% of low-grade tumors and

15% of high-grade tumors metastasized to the regional lymph nodes. Completely resectable low-grade tumors generally have an excellent prognosis without recurrence or development of metastases (12,16,17).

Our case underwent left thoracotomy and left lower lobectomy with removal of the left hilar, mediastinal and peribronchial lymph nodes and the postoperative course was uncomplicated. In our case, histopathological diagnosis of the tumor was low-grade MEC. Lymph nodes were free of tumor cells. The patient has been well and free of recurrence for 12 months postoperatively. Pathological diagnosis of the case reported by Kut et al. was intermediate grade MEC. Similarly their case was reported to have no recurrence during six years follow up (10).

Treatment of these tumors is surgical excision, the exact modality depending on the site and extent of the growth. Where clear margins are obtained, sleeve resection of the bronchus is the operation of choice. However, complete resection is essential, as low-grade tumors have been known to recur locally (17). With delay in diagnosis, irreversible changes in the lung parenchyma can occur, requiring lobectomy or even pneumonectomy.

In summary, low grade MEC have an excellent prognosis if they can be resected completely, especially children. Therefore, in cases of unexplained obstructive symptoms or recurrent pneumonias or persistent atelectasis, FFB should be considered to readily identify suspicious signs.

REFERENCES

1. Smetana HF, Iverson L, Swan LL. Bronchogenic carcinoma: An analysis of 100 autopsy cases. *Milit Surg* 1952; 111: 335-51.
2. Kim TS, Lee KS, Han J, et al. Mucoepidermoid carcinoma of the tracheobronchial tree: Radiographic and CT findings in 12 patients. *Radiology* 1999; 212: 643-8.
3. Kim J, Park C, Kim K, et al. Surgical resection of mucoepidermoid carcinoma at the carina in a 9-year-old boy. *J Pediatr Surg* 1998; 33: 1561-2.
4. Torres AM, Ryckman FC. Childhood tracheobronchial mucoepidermoid carcinoma: A case report and review of the literature. *J Pediatr Surg* 1988; 23: 367-70.
5. Cohen MC, Kaschula ROC. Primary pulmonary tumors in childhood: A review of 31 years' experience and the literature. *Pediatr Pulmonol* 1992; 140: 222-32.
6. Merran, S. Case no. 1: Diagnosis; mucoepidermoid carcinoma of the left bronchus. *J Radiol* 1999; 80: 1714-5.
7. Hancock BJ, Di Lorenzo M, Youssef S, et al. Childhood primary pulmonary neoplasms. *J Pediatr Surg* 1993; 28: 133-6.
8. Dinopoulos A, Lagona E, Stinios I, et al. Mucoepidermoid carcinoma of the bronchus. *Pediatr Hematol Oncol* 2000; 17: 401-8.
9. Desai DP, Mahoney EM, Miller RP, Holinger LD. Mucoepidermoid carcinoma of the trachea in a child. *Int J Pediatr Otolaryngol* 1998; 45: 259-63.
10. Kut A, Karadag B, Karakoc F, et al. Mucoepidermoid carcinoma of the bronchus: A rare entity in childhood. *Pediatr Int* 2005; 47: 203-5.
11. Öz N, Sarper A, Karaveli Ş, et al. A rare trachea malign tumour: Mucoepidermoid carcinoma (Case report). *Tuberk Toraks* 2004; 52: 83-5.
12. Yousem SA, Hochholzer L. Mucoepidermoid tumors of the lung. *Cancer* 1987; 60: 1346-52.
13. Kumar L, Singh M, Mitra SK, Bannerjee CK. Superadded aspergillosis on carcinoid bronchial adenoma leading to delayed diagnosis. *Postgrad Med J* 1990; 66: 938-9.
14. Nishi J, Yoshinaga M, Noguchi H, et al. Bronchial polyp in a child with endobronchial tuberculosis under fiberoptic bronchoscopic observation. *Pediatr Int* 2000; 42: 573-6.
15. Santambrogio L, Cioffi U, De Simone M, et al. Video-assisted sleeve lobectomy for mucoepidermoid carcinoma of the left lower lobar bronchus. *Chest* 2002; 121: 635-6.
16. Colby TV, Koss MN, Travis WD. Tumors of salivary gland type. Tumors of the lower respiratory tract: AFIP atlas of tumor pathology. 3rd series. Vol 13. Washington DC: American Registry of Pathology, 1995: 65-89.
17. Heitmiller RF, Mathisen DJ, Ferry JA, et al. Mucoepidermoid lung tumors. *Ann Thorac Surg* 1989; 47: 394-9.