

---

# Is tin fume exposure benign or not? Two case reports

Ayşe YILMAZ<sup>1</sup>, Serpil GÖÇMEN ÖCAL<sup>1</sup>, Sibel DORUK<sup>1</sup>, Berat ACU<sup>2</sup>

<sup>1</sup> Gaziosmanpaşa Üniversitesi Tıp Fakültesi, Göğüs Hastalıkları Anabilim Dalı,

<sup>2</sup> Gaziosmanpaşa Üniversitesi Tıp Fakültesi, Radyoloji Anabilim Dalı, Tokat.

## ÖZET

**Kalay toz-buharı maruziyeti benign midir yoksa değil midir? İki olgu sunumu**

*Stannosis, kalay (tin-oksit/stannik oksit) toz ve buhar inhalasyonunun sonucu olarak kalayın pulmoner parankimde biriktiği fibrotik olmayan bir pnömokonyozdur. Göğüs radyografisinde her iki akciğerde çok sayıda ve dens nodüller vardır. Stannozisin radyolojik bulgularının aşikar olmasına rağmen hastalar klinik olarak iyi durumdadır ve solunum fonksiyon testi değerlerinde sapma yoktur. Dört yıldır efor dispnesi olan 70 yaşında erkek hasta. Kırk yıldır kalaycılık yapıyordu. Solunum fonksiyon testinde hafif restriksiyon saptandı. Göğüs grafisinde yaygın, küçük, dens retikülonodüler opasiteler vardı. Toraksın yüksek çözünürlüklü bilgisayarlı tomografisinde dens, yaygın nodüler lezyonlar, retikülasyon ve bal peteği görünümü vardı. Elli yaşında kadın hasta. Otuz üç yıldır kalay tozuna maruziyeti vardı ve hiç sigara içmemişti. Solunum fonksiyon testinde normal FVC ve hafifçe düşük FEV<sub>1</sub> değeri saptandı. Göğüs grafisinde yaygın retikülonodüler opasiteler saptandı. Toraks yüksek çözünürlüklü bilgisayarlı tomografide, bazı bölgelerde buzlu cam dansiteler, yaygın interlobüler septal kalınlaşmalar, her iki akciğerde perihiler bölgede belirgin olan peribronşiyal kalınlaşmalar ve sağ akciğerin üst ve orta lobunda subplevral milimetrik nodüler dansiteler gözlemlendi. Kalay tozu maruziyeti olan iki hasta tanımlanmıştır. Bununla birlikte, beklenenin aksine her iki hasta da klinik olarak kötüleşti ve solunum yetmezliği nedeniyle öldü.*

**Anahtar Kelimeler:** Stannosis, kalay tozu/buharı, pnömokonyoz, solunum yetmezliği.

## SUMMARY

**Is tin fume exposure benign or not? Two case reports**

Ayşe YILMAZ<sup>1</sup>, Serpil GÖÇMEN ÖCAL<sup>1</sup>, Sibel DORUK<sup>1</sup>, Berat ACU<sup>2</sup>

<sup>1</sup> Department of Chest Disease, Faculty of Medicine, Gaziosmanpasa University, Tokat, Turkey.

<sup>2</sup> Department of Radiology, Faculty of Medicine, Gaziosmanpasa University, Tokat, Turkey.

---

## Yazışma Adresi (Address for Correspondence):

Dr. Ayşe YILMAZ, Gaziosmanpaşa Üniversitesi Araştırma ve Uygulama Hastanesi, Göğüs Hastalıkları Anabilim Dalı 60100  
TOKAT - TÜRKİYE  
e-mail: ayse1106@mynet.com

*Stannosis is a non-fibrotic form of pneumoconiosis in which tin-oxide is accumulated in pulmonary parenchyma as a result of inhalation of tin-oxide (stannic oxide) dust and fume. Chest radiograph shows numerous small very dense nodules in both lungs. Although radiological findings of stannosis were apparent, the patients were clinically in good condition, and pulmonary function test (PFT) values showed no disability. Case 1, 70-year-old man had exercise dyspnea for four years. He worked as a tinner for 40 years. A slight restriction was detected in his PFT. Diffused, small, dense, reticulonodular opacities were detected on chest X-ray. Thorax high resolution computerized tomography (HRCT) revealed dense, common nodular lesions, reticulation and honeycomb appearance. Case 2, the patient was a 50-year-old woman. She had been exposed tin fume for 33 years and never smoked. In PFT, a slightly low FEV<sub>1</sub> value and a normal FVC value were detected. Diffused reticulonodular opacities were detected on chest X-ray. On thorax HRCT, ground glass densities in some areas, widespread interlobular septal thickening, peribronchial thickening predominant in perihilar regions in both lungs and subpleural millimetric nodular densities were observed in the upper and middle lobe of the right lung. Two patients who exposed to tin fume are described. However, contrary to what is expected, both patients clinically deteriorated and died as a result of respiratory failure.*

**Key Words:** Stannosis, tin oxide, pneumoconiosis, respiratory failure.

Stannosis is a non-fibrosing pneumoconiosis, in which tin-oxide is accumulated in pulmonary parenchyma as a result of inhalation of tin fume and dust. Although radiological findings of stannosis are apparent, there is generally no tissue reaction (1,2).

Releases of tin to environmental media may occur from the production, use, disposal, and recovery of tin and tin compounds. Gases, dusts, and fumes containing tin may be released from smelting and refining processes, industrial uses of tin, waste incineration, and burning of fossil fuels (3).

Tin compounds are found in various environmental media in both inorganic and organic forms. Tin may be released to the environment from natural and anthropogenic sources.

Occupational stannosis can be diagnosed in non-mining industry like grinding, briquette-making, smelting and casting process in which molten tin is used (1).

Exposure to tin fumes, as in the present case, can also occur during fusion operations when it reaches the melting point temperature (2).

Radiologically, there are numerous small very dense nodules in both lungs and the patients were clinically in good condition. Surprisingly, there were honeycomb appearances on thorax computed tomography (CT) of our cases. Again, our cases were interesting because of progressive

clinical deterioration. Therefore clinical findings of our patients were not typical for stannosis.

## CASE REPORTS

### Case 1

The patient was a 70-year-old man. He worked as a tinner for 40 years. There were exposures to biomass fuels, but patients had no exposures to other sources such as asbestos and silicates. He had exercise dyspnea for four years. He had a pain complaint at left chest area with effort which was relieved after resting. He had a history of 40 packs of cigarettes/year, and hypertension, diabetes mellitus and coronary artery disease. End-inspiratory crackles were detected at the left lung base. A slightly restriction was detected in his pulmonary function test (PFT) (PFT; FVC: 76%, FEV<sub>1</sub>: 93%; FEV<sub>1</sub>/FVC: 94%). Diffused, small, dense, reticulonodular opacities were detected on chest X-ray (Figure 1). A high resolution computerized tomography (HRCT) revealed dense, common nodular lesions, reticulation and honeycomb appearance with basal and peripheral predominance (Figure 2).

### Case 2

The patient was a 50-year-old woman. She was exposed to tin fume for 33 years. There were exposures to biomass fuels and asbestos but patients had no exposures to other sources such as silicates. She had never smoked. She presented with exercise dyspnea for 1.5 years, coughing

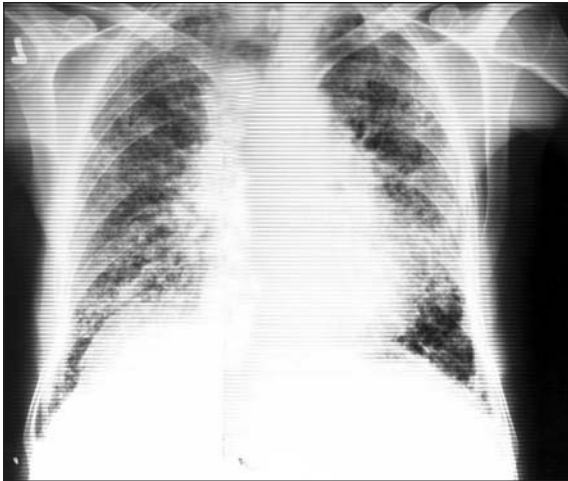


Figure 1. Diffused, small, dense, reticulonodular opacities.

for four months and occasional wheezing. She had kyphoscoliosis. Erythrocyte sedimentation rate (50 mm/hour) was high. She had mild hypoxemia ( $\text{PaO}_2$ : 75 mmHg,  $\text{SaO}_2$ : 96%) and respiratory alkalosis (pH: 7.48). In PFT, a slightly low  $\text{FEV}_1$  value and a normal FVC value were detected (FVC: 82%,  $\text{FEV}_1$ : 75%,  $\text{FEV}_1/\text{FVC}$ : 78%). Common nodular lesions were apparent on chest X-ray. The right hilus was opaque. On thorax HRCT, ground glass densities in some areas, widespread interlobular septal thickening, peribronchial thickening pre-dominantly perihilar in both lungs and many small (about 3 mm

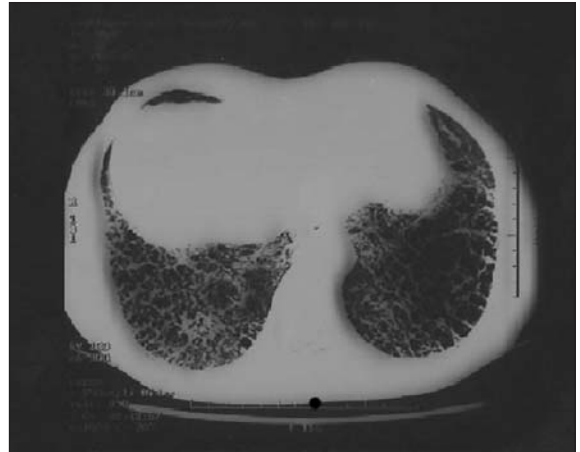


Figure 2. Honeycomb appearance with peripheral and basal predominance.

in diameter) subpleural nodules with metallic density were observed in the upper and middle lobe of the right lung (Figure 3,4). Fiberoptic bronchoscopy showed no endobronchial lesion. Bronchial lavage smear and culture were negative for acid-fast bacilli. Bronchial lavage cytology revealed class II, and histiocytic cells and focal fibrosis were detected on transbronchial lung biopsy.

On the first admission, two patients looked well. Their body temperatures, blood pressures, pulses and respiratory rates were normal and digital clubbing and peripheral cyanosis were ab-

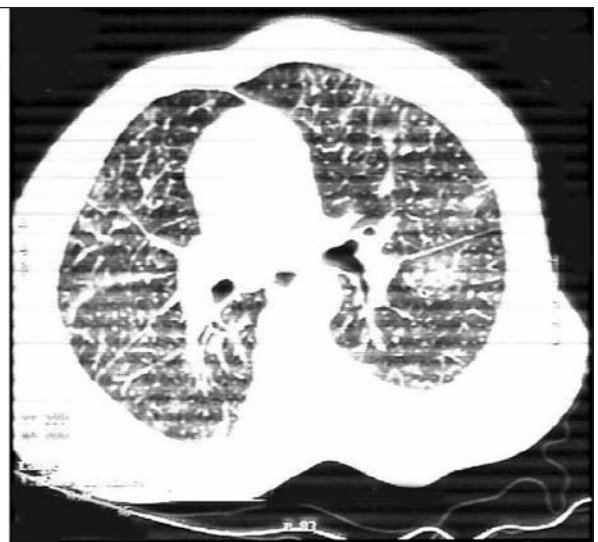



Figure 3,4. Thorax HRCT revealed ground glass densities in some areas, widespread interlobular septal thickening, peribronchial thickening predominantly perihilar in both lungs and many small subpleural nodules with metallic density, and end-stage fibrosis.

sent. Both patients had not come for the check-ups in recommended periods. The first patient showed up with a respiratory failure about eight months later and died 40 days later. Similarly, the second patient died in another center six months later due to respiratory failure.

## DISCUSSION

We presented here two patients with stannosis. Our cases were exposed to smelting gases or vapors of tin. Occupational history and pulmonary radiography supported helped the diagnosis of stannosis.

Occupational exposure to tin-oxide dust or fumes induces stannosis, with no indication of fibrosis or apparent disability beyond chest X-ray opacities.

This condition is not associated with fibrosis and appears not to be associated with any apparent lung dysfunction. The literature on long-term inhalation of inorganic tin consists mainly of case-reports in humans, with poor exposure assessment and old methods of examination. Reports on effects concerning microscopic pathology and cell toxicity in the respiratory system are scarce. The information is insufficient to assess the health risk to the lungs.

There are several case reports of workers exposed to dust and fume for three years or more in tin smelting works, scrap metal recovery plants and hearth tinning. The only positive finding is the chest X-rays presenting a pneumoconiosis called stannosis (4). Dundon and Hughes presented a case with "peculiar widespread mottling of both lung fields by discrete shadows" on the chest roentgenogram in a man who died ten years later of metastatic prostate carcinoma. He had been employed in an industry involving a detinning furnace for 18 years (5). The authors also reported that there was a honeycomb appearance with narrow dark gray to black pigmented zones outlining and encircling the slightly dilated airspaces on sections. The authors also reported honeycomb appearance in the pathological sections of the same patients (5). This honeycomb appearance was also observed in our patients.

Examined in a health assessment of the employees including retired workers from a United Kingdom tin smelting unit, Robertson et al. described chest X-ray changes in 121 out of 215 workers. The changes were widespread, tiny, dense shadows; or softer, larger, more nodular opacities. Typical changes were found in workers handling raw ore, smelting furnace house workers and refinery furnace men. Employment time ranged from three to 50 years. None of the subjects had any clinical symptoms or signs referable to pneumoconiosis. None of the chest X-rays suggested fibrosis or significant emphysema (6,7).

Lung function measurements showed no changes that lead to disability whatever the radiographic category was (8). Consistently, our cases' respiratory functions revealed restrictive abnormality most probably due the deposition of tin-oxide in the lung interstitium. Güllü et al. presented a tinner with stannosis and tuberculosis (9). There was restrictive abnormality on the PFT of their cases. In addition, there was honeycomb appearance, end-stage fibrosis, structural distortion, and tractional bronchiectasis on thorax CT (9). Our cases had findings in accordance with these.

Oyanguren et al. demonstrated a proliferative reaction characterized by fibroblastic proliferation of adult connective tissue cells after intraperitoneal injection of concentrated tin dust to 18 guinea pigs (10). Their results supported the presence of nodular opacities with fibrosis in our cases.

Robertson et al. studied the autopsy findings of the lungs of seven tin workers, died of other diseases. The dust foci containing dust-laden macrophages were seen around respiratory bronchioles and less commonly around segmental bronchi, in the alveoli, interlobular septa, pleura and perivascular lymphatics. No silicotic and fibrous nodules or no significant pulmonary fibrosis were seen. Chemical and X-ray diffraction analyses showed that the lungs contained SnO<sub>2</sub>, the fully oxidized state of tin metal. X-ray emission microanalysis identified tin in a minute particle of dust in lung phagocytes. Although the smooth muscle of the bronchiole appears intact,

its function may be progressively embarrassed by the cuff of dust-laden macrophages and the network of reticulin (11).

Schuler et al. conducted clinical studies over 19 workmen selected based on tin-oxide dust and fume exposure at a plant under investigation. In no case was there an impairment of pulmonary function. On this basis one person was classified as completely normal, eight were classified as suspected stannosis and 10 were considered to have tin-oxide pneumoconiosis. Persons with less than three years of exposure may be classified either as normal or suspects, but do not present pulmonary nodulation. After three years exposure to the environmental conditions of the plant under study, nodular stannosis was found in all cases, and advanced stages occurred with increasing frequency as years of exposure increased. Two of the affected subjects had moderate anorexia, one experienced scapular pain. No significant degree of obstructive emphysema or of diffuse pulmonary fibrosis existed in the cases studied (12).

Our cases were concluded to be stannosis because of long tin exposures, lack of any pathology that can account for interstitial disease and clear and consistent radiological findings.

Existing fibrosis with honeycomb appearance on chest X-rays and respiratory failure are not a typical feature of this pneumoconiosis.

This may be due to another possible co-existent factor in work place.

We can conclude that it is possible that tin fume exposure is not as benign as believed.

## REFERENCES

1. Sluis-Cremer GK, Thomas RG, Goldstein B. Stannosis. A report of two cases. *South African Medical Journal* 1989; 75: 124-6.
2. Tan Sri dates (Dr) Abu Bakar Bin Suleiman director general of health. Malaysia. August 1997. Members of the national technical committee for surveillance of occupational lung diseases in Malaysia. Available from: <http://dph.gov.my/guidelines/occuhealth/lung/chapter12.htm>.
3. Concise International Chemical Assessment Document 65. Tin and Inorganic Tin Compounds. Geneva: World Health Organization, 2005.
4. Westrum B, Thomasse Y. The Nordic Expert Group for Criteria Documentation of Health Risks from Chemicals and the Dutch Expert Committee on Occupational Standards. 130. *Arbete och Hälsa* 2002; 10. Tin and inorganic tin compound. Available from: [http://ebib.arbetslivsinstitutet.se/ah/2002/ah2002\\_10.pdf](http://ebib.arbetslivsinstitutet.se/ah/2002/ah2002_10.pdf).
5. Dundon CC, Huges JP. Stannic oxide pneumoconiosis. *American Journal of Roentgenology, Radium Therapy & Nuclear Medicine* 1950; 63: 797-812.
6. Robertson AJ. Pneumoconiosis due to tin oxide. In: King EJ, Fletcher CM (eds). *Symposium on Industrial Pulmonary Disease*. Boston: Little Brown, 1960: 168-84.
7. Robertson AJ, Whitaker PH. Radiological changes in pneumoconiosis due to tin oxide. *Journal of the Faculty of Radiologist* 1955; 6: 224-33.
8. Robertson AJ. The romance of tin. *Lancet* 1964; 41: 1289-93.
9. Güllü E, Karnak D, Kayacan O, et al. A tinner with stannosis and tuberculosis. *Case Report. Clin Pract Rev* 2005; 6: 73-6.
10. Oyanguren H, Haddad R, Maass H. Stannosis. *Industrial Medicine Surgery* 1958; 27: 427-31.
11. Robertson AJ, Rivers D, Nagelschmidt G, et al. Stannosis: Benign pneumoconiosis due to tin oxide. *Lancet* 1961; 1: 1089-93.
12. Schuler P, Cruz E, Guijon C, et al. Stannosis: Benign pneumoconiosis owing to inhalation of tin dust and fume. *Industrial Medicine Surgery* 1958; 27: 432-5.