
Mycobacterium simiae infection in an immunocompetent patient, with DNA analyses verification

Zeynep Pınar ÖNEN¹, Zeynep Ceren KARAHAN², Öznur AKKOCA YILDIZ¹, Gülseren KARABIYIKOĞLU¹

¹ Ankara Üniversitesi Tıp Fakültesi, Göğüs Hastalıkları Anabilim Dalı, Ankara,

² Ankara Üniversitesi Tıp Fakültesi, Çocuk Sağlığı ve Hastalıkları Anabilim Dalı, Moleküler Patoloji ve Genetik Laboratuvarı, Ankara.

ÖZET

Bağışıklığı baskılanmamış olguda, DNA analizi ile doğrulanmış *Mycobacterium simiae* enfeksiyonu

Mycobacterium simiae, atipik bir mikobakteridir. Genellikle, bağışıklık sistemi AIDS gibi bir nedenle baskılanmayan kişilerde hastalık oluşturmaz. Biz de bağışıklık sistemi baskılanmamış, geçirilmiş tüberküloz öyküsü olan bir kadın olguda, *M. simiae* nedeniyle pulmoner enfeksiyon tablosunu sizlerle paylaşmak istedik.

Anahtar Kelimeler: *Mycobacterium simiae*, tüberküloz dışı mikobakteri.

SUMMARY

***Mycobacterium simiae* infection in an immunocompetent patient, with DNA analyses verification**

Zeynep Pınar ÖNEN¹, Zeynep Ceren KARAHAN², Öznur AKKOCA YILDIZ¹, Gülseren KARABIYIKOĞLU¹

¹ Department of Chest Diseases Faculty of Medicine, Ankara University, Ankara, Turkey,

² Molecular Pathology and Genetics Laboratory, Department of Children Health and Diseases Faculty of Medicine, Ankara University, Ankara, Turkey.

Yazışma Adresi (Address for Correspondence):

Dr. Zeynep Pınar ÖNEN, Ankara Üniversitesi Tıp Fakültesi, Göğüs Hastalıkları Anabilim Dalı, Dikimevi ANKARA - TÜRKİYE

e-mail: zponen@yahoo.com

Mycobacterium simiae is a non-tuberculosis mycobacterium that does commonly cause clinical disease in immunocompromised patients with or without AIDS. We describe a case of *M. simiae* pulmonary infection in a patient without immunodeficiency syndrome, who had a history of *Mycobacterium tuberculosis* infections.

Key Words: *Mycobacterium simiae*, non-tuberculosis mycobacterium.

Since 1982, the frequency of diseases attributed to non-tuberculosis mycobacteria has increased, especially in HIV/AIDS patients and person's immune compromising on account of cancer, transplantation or administration of immunosuppressive drugs (1). *Mycobacterium simiae* is a non-tuberculosis mycobacterium which was first isolated from *Macacus rhesus* monkeys in 1965 by Karasseva and associates (2). Later it was isolated from environmental sources in the Middle East. These bacteria are ubiquitous and may be found every where in the environment. In contrast to *Mycobacterium tuberculosis*, non-tuberculosis mycobacterium does not commonly cause clinical disease and interpersonal transmission does not occur (1,3). However it was not clear if it was a pathogen or colonizer of the respiratory tract. Nowadays *M. simiae* has been isolated repeatedly from the sputum of patients with chronic lung disease and patients with tuberculosis cavitory disease. Extra pulmonary diseases in presumed immune competent hosts have been reported in some patients. However the clinical spectrum of the *M. simiae* infection is not yet known, nor is the evolution of the disease when it is being treated. Most cases of *M. simiae* have been from tropical and subtropical regions and also appear to be increase in prevalence particularly in certain geographic locations and chronic pulmonary infections. *M. simiae* is not a common isolate from patients in Asia and it is usually associated with HIV or immune suppression. Also these infections are difficult to treat and do not respond to traditional anti-tuberculosis medications. However novel antimicrobial combinations that include clarithromycin or azithromycin have been shown to be effective. We report a case of lung infection due to *M. simiae* in an immune competent patient (4,5).

CASE REPORT

A 47-year-old woman was admitted to our hospital from Cyprus with a history of *M. tuberculosis* pulmonary infections in 1993 and 2002. Between 2002 and 2004 she did not have any pulmonary problems. At the admission her symptoms were pleuretic chest pain, cough with sputum, fever and weight loss. There was no history of contact with monkeys but she was living with domestic animals and using surface water in her daily life. Low blood pressure (80/50 mmHg), fever (38°C), were revealed on physical examination. Crackles were the pulmonary symptoms. The leukocyte count was 7200/mm³, hemoglobin level was 10.7 mg/dL, platelet count and results of biochemical studies were normal. The erythrocyte sedimentation rate was 92 mm/hour. C-reactive protein was 110 mg/dL. Her immunological parameters were normal and HIV was serologically negative (at the admission and after 6 weeks later). Analysis of chest radiographs revealed nodular infiltrates on the lower lung zone of the left lung (Figure 1). High resolution computed tomography revealed cystic and varicose bronchiectasis, some of them were filled with mucus and tree in bud, multiple micronodular infiltrates on both lung fields. Cavitations and consolidation were reported in the lingula (Figure 2). Microscopic examination of sputum revealed many acid-fast bacilli. Bronchoscopic examination did not reveal anatomic abnormalities of the bronchial tree. Also the microscopic examination of a tissue specimen obtained by use of bronchoalveolar lavage (BAL) revealed many aside-fast bacilli. Both the sputum and the BAL samples were processed according to common protocols for bacteria, fungi and mycobacterium. The cultures yielded a heavy growth of mycobacterium but the phenotypic characteristics were other than *M. tuberculosis*. From culture specimens, DNA was isolated by the glass-bead method.

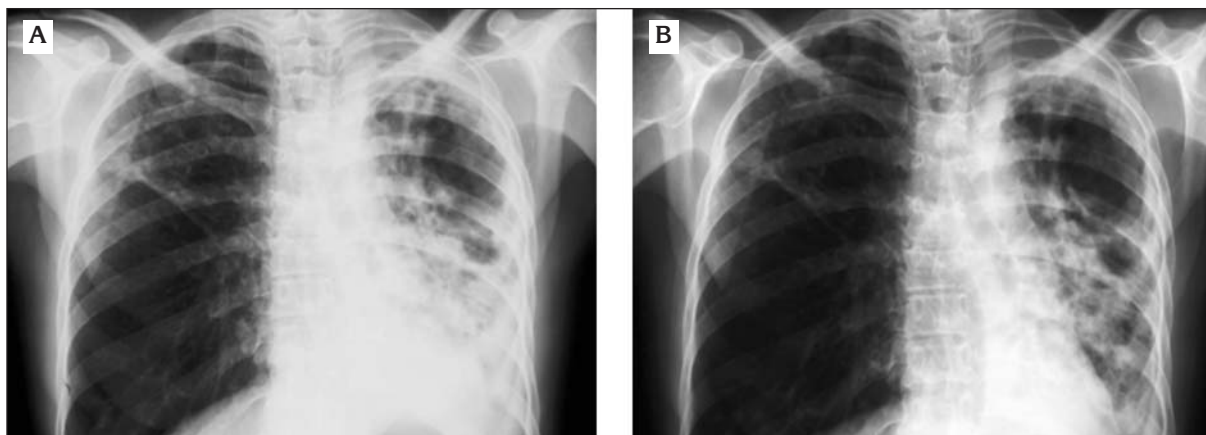


Figure 1.a. Chest X-ray at the admission revealed nodular infiltrates on the lower lung zone of the left lung. 1.b. Radiological improvement after the therapy.

Sputum was decontaminated by Modified Petroffs' method prior to DNA extraction. From the decontaminated specimen DNA was extracted by classical phenol-chloroform extraction method. A 430 bp fragment between positions 398 and 836 of the published 65-kDa heat shock protein of *M. tuberculosis* was amplified by polymerase chain reaction (PCR) (6). The reaction was performed by using the primers Tb11 (5'ACCAACGATGGTGTGTCCAT3') and Tb12 (5'CTTGTCGAACCGCATACCCT 3') as described previously (7). The products of culture and sputum isolates were visualized under UV after ethidium bromide staining. In order to determine the species of the amplified products, 12.5 µL of the polymerase chain reaction (PCR) products

were digested with 10 U of Eco91I (Fermentas, Lithuania) and HaeIII (Promega, USA) restriction endonucleases. The Eco91I digestions gave 245 and 220 bp products, and HaeIII digestions gave 200 and 135 bp products which corresponded to *M. simiae* (Telenti A, 1993). In order to confirm this result, the PCR products were subjected to automated sequence analysis. Prior to sequencing, the PCR products were purified by using E.Z.N.A. Cycle-Pure Kit (Omega Bio-tek, Doraville-USA) according to the manufacturer's instructions. Automated sequence analysis was performed by automated sequence analyzer (CEQ2000 XL, Beckman Coulter, USA) using the same primers as PCR amplification. The obtained sequences were searched through the

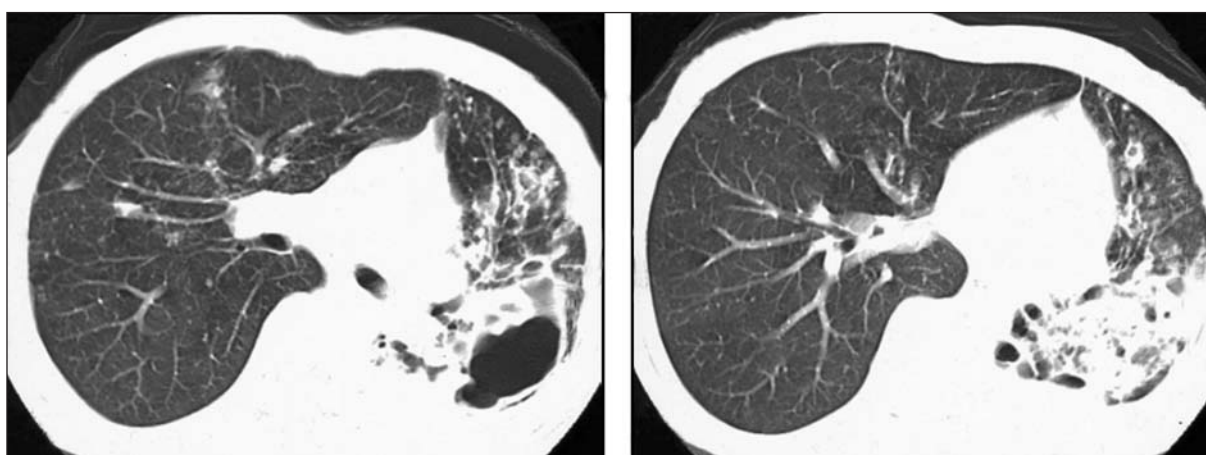


Figure 2. High resolution CT at the admission revealed cystic and varicose bronchiectasis, some of them were filled with mucus and tree in bud, multiple micro nodular infiltrates on both lung fields. Cavitations and consolidation were seen in the lingula.

Gen Bank sequences by using the nucleotide-nucleotide BLAST link of the Gen Bank and sequences of our isolates were found to match to *M. simiae* hsp-65 gene with 97-98% sequence similarity.

The patient was treated with rifampin, isoniazid, pyrazinamide and ethambutol for two months. In vitro susceptibility test results showed complete susceptibility to the first line treatment but there were no clinical, radiological or bacteriological improvement. After the verification of *M. simiae* with molecular analysis clarithromycin added to the treatment and continued for more two months. The patient improved clinically and radiographically next eight months (Figure 1). Subsequent cultures of sputum were negative, PCR of sputum were serologically negative and the patient remained asymptomatic since then.

DISCUSSION

M. simiae is a slow growing photochromogen mycobacterium, that shares some phenotypic properties with *M. avium* complex. It is an environmental organism recovered from surface water, soil, milk, food products, both domestic and wild animals. The mechanism of transmission is not clear. Clinical disease occurred in Israel, Madagascar, Arizona, Texas and Guadelupe but the ecology is not well understood, also it is difficult to isolate mycobacterium from nature, so published results underestimate reality (1,8,9). There is no epidemiological association between monkeys and increased incidence of association *M. simiae* isolation from humans. Published cases of clinical pulmonary disease usually involved patients with chronic lung disease, such as bronchiectasis or ancient mycobacterial disease (10,11). Most of these patients were immune compromised and had HIV/AIDS, undergoing corticosteroid therapy or had solid organ cancer. In recent years few cases of disseminated disease have been reported with AIDS (4,5,12,13).

This patient's case is unique, because there was laboratory confirmed no immune suppression. Perhaps an as yet undefined immune deficiency exist in these patients; abnormal production of

IFN-gamma, TNF-alpha, IL-12. All of these parameters were in normal range. She has never taken immunosuppressive therapy, HIV was serologically negative and there was any history or sign of malignancy. In prior reports, cases were living in specific locations; our case has been living in Cyprus which is an island in Mediterranean Sea. There was no other non-tuberculosis mycobacterium infection report from that island. Some of the cases of mixed disease have been reported and the clinical status was attributed to the other mycobacterium. In our case, the repeated PCR specimen represents, the only mycobacterium were *M. simiae*. It is likely that the bronchiectasis and prior mycobacterium infection contributed to the development of clinical *M. simiae* pulmonary infection.

She was presented with pulmonary disease as it was expected without HIV/AIDS patients (14). The plain radiographs demonstrate nodular and irregular infiltrates in the lower lung zone, particularly in lingula (Figure 1) (15). As it was seen in our patient, studies with high-resolution computed tomography have shown that, most of these patients have multiple micronodular infiltrates in addition to cystic bronchiectasis (Figure 2). Cavitations develop in advancing disease and presents with consolidation, usually of the right middle lobe or lingula. Clinical and radiological manifestations of the disease resembled these previously found in elderly thin woman, which is called as "Lady Windermere Syndrome" with *M. avium* complex (15).

Optimal therapy of *M. simiae* infection has not yet been determined. Response to therapy was poor. This may have been due to the advanced immune suppression status of the patients and the resistance of *M. simiae* to the most antituberculous drugs (4). In experimental murine infection clarithromycin significantly penetrates macrophages and inhibits the replication. Infected patients treated with combinations of multiple agents for long durations (16,17). The risk of adverse effects of treatment may in some cases out weight the potential benefits. This factor is much more important in benign cases as it is seen in our patient.

REFERENCES

1. Dailloux M, Laurain C, Weber M. Water and nontuberculous mycobacteria. *Water Res* 1999; 33: 2219-28.
2. Karasseva V, Weissfeiler J, Krasznay E. Occurrence of atypical mycobacteria in *Macacus rhesus*. *Acta Microbiol Acad Sci Hung* 1965; 12: 275-82.
3. Krasnow I, Gross W. *Mycobacterium simiae* infection in the United States. A case report and the discussion of the organism. *Am Rev Respir Dis* 1975; 111: 357-60.
4. Al-Abdely HM, Revankar SG, Graybill JR. Disseminated *Mycobacterium simiae* infection in patient with AIDS. *J Infect* 2000; 41: 143-7.
5. Bell RC, Higuchi JH, Donovan Wn, et al. *Mycobacterium simiae* clinical features and follow-up of twenty-four patients. *Am Rev Respir Dis* 1983; 127: 35-8.
6. Schinnick T. The 65-kilodalton antigen of *Mycobacterium tuberculosis*. *J Bacteriol* 1987; 169: 1080-8.
7. Telenti A, Marchesi F, Balz M, Bally F. Rapid identification of *Mycobacteria* to the species level by polymerase chain reaction and restriction endonuclease analysis. *J Clin Microbiol* 1993; 31: 175-8.
8. Weiszfeiler JG, Karasseva V, Karczag E. *Mycobacterium simiae* and related mycobacteria. *Rev Infect Dis* 1981; 3: 1040-5.
9. Arora R, Hagan L, Conger NG. *Mycobacterium simiae* infection in patient with common variable immunodeficiency. *J Allergy Clin Immunol Abstracts*; 113: 23.
10. Valero G, Peters J, Jorgensen JH, Graybill JR. Clinical isolates of *Mycobacterium simiae* in San Antonio, Texas. An 11-year review. *Am J Respir Crit Care Med* 1995; 152: 1555-7.
11. Rynkiewicz D, Cage GD, Butler WR, Ampel NM. Clinical and microbiological assessment of *Mycobacterium simiae* isolates from a single laboratory in Southern Arizona. *Clin Infect Dis* 1998; 26: 625-30.
12. Torres RA, Nord J, Feldman R, et al. Disseminated mixed *Mycobacterium simiae* *M. avium* complex infection in acquired immunodeficiency syndrome. *J Infect Dis* 1991; 164: 432-3.
13. Griffith DE, Aksamit T, Barbara A, et al. An official ATS/IDSA statement: diagnosis, treatment and prevention of nontuberculous mycobacterial diseases. *Am J Respir Crit Care Med* 2007; 75: 367-416.
14. Saro BB, Estaban J, Jimenez S. *Mycobacterium simiae* infection in an immunocompromised patient without Acquired immunodeficiency syndrome. *Clin Infect Dis* 2002; 34: 26-7.
15. Reich JM, Johnson RE. *M. avium* complex pulmonary disease presenting as an isolated lingular or middle lobe pattern. The lady Windermere syndrome. *Chest* 1992; 101: 1605-9.
16. Wolinsky E. Mycobacterial diseases other than tuberculosis. *Clin Infect Dis* 1992; 15: 1-12.
17. Tartaglione T. Treatment of nontuberculous mycobacterial infections: role of clarithromycin and azithromycin. *Clinical Therapeutics* 1997; 19: 626-38.