
Phrenic nerve injury due to thoracentesis for TPN effusion in a preterm newborn: consecutive two unusual complications

Ramazan ÖZDEMİR, Suna OĞUZ, Nurdan URAS, Ömer ERDEVE, Yavuz YILMAZ, Hülya ULU, Uğur DİLMEN

SB Zekai Tahir Burak Doğumevi Eğitim ve Araştırma Hastanesi, Yenidoğan Yoğun Bakım Ünitesi, Ankara.

ÖZET

Preterm bir yenidoğanda TPN efüzyonu için yapılan torasenteze bağlı frenik sinir hasarı: Ardışık iki sıra dışı komplikasyon

Santral venöz kateterler yenidoğan yoğun bakım ünitelerinde parenteral beslenme yolu olarak yaygın şekilde kullanılmaktadır. Yenidoğanlarda parenteral beslenme sıvı ekstrasvazyonuna bağlı plevral efüzyon santral venöz kateterlerin nadir bir komplikasyonudur. Frenik sinir hasarından dolayı diyafram paralizi bebeklerde yaşamı tehdit edici olabilen nadir bir solunum durumudur.

Anahtar Kelimeler: Plevral efüzyon, diyafram paralizi, yenidoğan.

SUMMARY

Phrenic nerve injury due to thoracentesis for TPN effusion in a preterm newborn: consecutive two unusual complications

Ramazan ÖZDEMİR, Suna OĞUZ, Nurdan URAS, Ömer ERDEVE, Yavuz YILMAZ, Hülya ULU, Uğur DİLMEN

Neonatal Intensive Care Unit, Zekai Tahir Burak Maternity Training and Research Hospital, Ankara, Turkey.

Central venous catheters are commonly used in neonatal intensive care units as routes of parenteral nutrition. Plevral effusions caused by extravasation of parenteral alimentation fluid are a rare complication of central venous catheters in the newborn. Diaphragmatic paralysis due to phrenic nerve injury is a rare respiratory condition which may be life-threatening in infants.

Key Words: Plevral effusion, diaphragm paralysis, newborn.

Yazışma Adresi (Address for Correspondence):

Dr. Ramazan ÖZDEMİR, SB Zekai Tahir Burak Doğumevi Eğitim ve Araştırma Hastanesi, Yenidoğan Yoğun Bakım Ünitesi, Altındağ, ANKARA - TÜRKİYE

e-mail: ramazanoz@yahoo.com.tr

Insertion of an intravascular catheter is the most common invasive procedure in the neonatal intensive care units (NICU) (1). The catheters serve as routes for blood sampling, blood pressure monitoring, and infusion of intravenous fluids, total parenteral nutrition (TPN) and medications. They also can be used during resuscitations, exchange transfusions, and critical care monitoring or for prolonged nutritional and medication support (1,2). There are various complications associated with the insertion of central venous lines despite the advances made in the design, material of the catheter and the technique of insertion. Vascular erosion from the catheter is a rare complication (3). Vascular erosion by central venous catheters occurs when the catheter breaches the blood vessel wall, resulting in extravasation of TPN into the pleural cavity (4). Extravasation of TPN into the pleural cavity has been reported in older patients. However, few of these complications have been reported in the neonatal period. Extravasation into the pleural cavity is treated with the intercostal drainage (thoracentesis) (5).

Although many complications dealing with the thoracentesis are reported, direct injury to the phrenic nerve is very rare (6,7).

Herein, we will report a preterm baby with diaphragm evantration due to phrenic nerve injury after intercostal drainage which was applied to treat the extravasation of TPN. To the best of our knowledge, this is the first case report in the literature with both of these rare complications.

CASE REPORT

A male infant born vaginally, 28 weeks gestational age, 1250 g body weight, was admitted to the NICU. Apgar scores were 7 and 9 at 1st and 5th minutes, respectively. During the first days of life he required continuous positive nasal airway pressure and parenteral nutrition via an umbilical central venous catheter. He received ibuprofen for closure of patent ductus arteriosus. On day 16th, he had necrotizing enterocolitis and a central venous catheter was placed into the left subclavian vein for fluid replacement and parenteral nutrition. A chest X-ray film to check the position of the catheter demonstrated normally positioned hemidiaphragms. On 18th day, the patient suddenly presented with respiratory compromise, with tachypnoea, tachycardia and sudden increase in her oxygen requirements requiring mechanical ventilation. Heart sounds and breath sounds on the left hemithorax were difficult to hear. The chest X-ray showed a large amount of fluid in the left pleural space and a slight mediastinal shift. A chest tube was placed to drain the hydrothorax (Figure 1). The

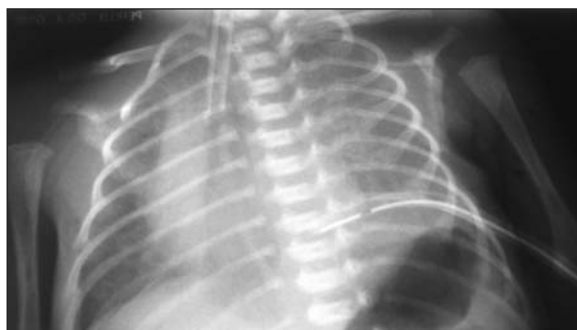

Figure 1. Chest X-ray showed a large amount of fluid in the left pleural space and a slight mediastinal shift and a chest tube was placed to drain the hydrothorax.

performed thoracentesis resulted in obtaining a milky-white liquid, chemically identical to TPN. The results of the biochemical analysis of the fluid were: glucose: 953 mg/dL, LDH: 56 IU/L, amylase: 11.5 IU/L, total protein: 0.17 g/dL, cholesterol: 70 mg/dL and triglycerides: 1230 mg/dL. TPN was stopped and the central venous catheter was removed once TPN leakage was suspected. Clinical examination showed that there was leakage of TPN fluid at the central line site.

On the 26th day chest tube was replaced depending on the attempts to wean the patient from the ventilator were unsuccessful. He appeared distressed and hypoxic even on continuous positive airway pressure. On physical examination breath sounds were absent over the lower half of the left chest. Chest X-ray showed elevation of the left hemidiaphragm and ultrasonography of the diaphragm demonstrated absent movement during spontaneous breathing (Figure 2). The infant underwent to thorotomy and plication of the left hemidiaphragm. He was successfully extubated on the second postoperative day. After three days of nasal continuous positive airways pressure, he subsequently required only 25% of supplementary oxygen. A chest X-

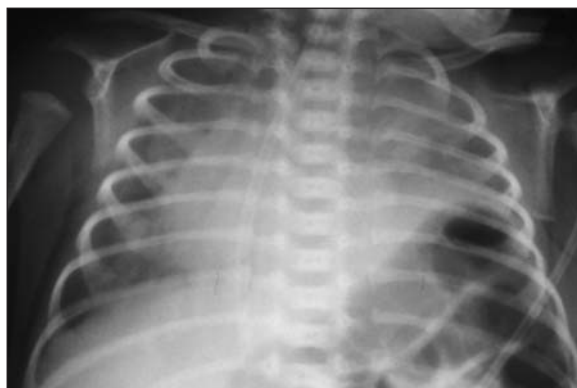


Figure 2. Chest X-ray demonstrating elevation of left hemidiaphragm with mediastinal shift to the right.

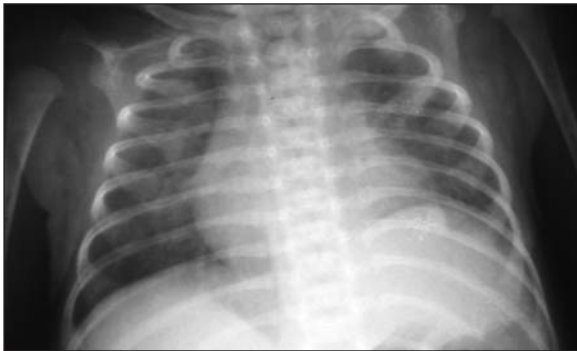


Figure 3. Follow-up chest X-ray demonstrating normal position of left hemidiaphragm.

ray 3 weeks later showed reexpansion of the left lung with normal diaphragmatic position (Figure 3). He was eventually discharged to home at 38 days of age.

DISCUSSION

Central venous catheters (CVCs) provide stable intravenous access to infants who need long-term parenteral alimentation or medications. Complications from CVCs include injury to other vessels or organs during insertion, catheter migration or malposition with extravasation from the malpositioned catheter causing further problems, infection, thromboembolism, catheter breakage, and dysfunction (1). Pleural effusions caused by extravasation of parenteral alimentation fluid are a rare complication of CVCs in the newborn. The incidence of vascular erosion has been difficult to quantify as almost all of the available information stems from case reports. One series, which involved 1058 catheters, had an incidence of 0.4% (8). The other series, erosion had an incidence per catheter of 0.7% and was likely to occur in left-sided catheters (4). The extravasation of TPN due to vascular erosion was also on the left side in our patient, compatible with the literature.

A milky-white effusion in the left pleural space can result from disruption of the main thoracic duct high in its course, long-standing fluid collection in patients suffering from tuberculosis or malignant thoracic lesions (pseudochylothorax), leakage of parenteral nutrition or infected effusive processes (9,10). In our patient, the diagnostic thoracentesis fluid was milky in color and its biochemical evaluation was compatible with TPN. There was no propagation on the cultures of the fluid and moreover there was no history of tuberculosis in the mother of our baby. Respiratory distress resulting from pleural effusions may arise within a few hours or several days after placement of the catheter. Diagnosis in all cases was by means of chest drain insertion and aspi-

ration of large quantities of pleural fluid, described to be of milky appearance. Diagnosis and management are often delayed, leading to increased morbidity and mortality. Our patient typically presented with symptoms of breathlessness or chest discomfort at about second days after catheter insertion.

Chest drains incorporate the use of a one-way valve to drain fluid or air from the pleural cavity. Chest drain insertion in infants has been associated with a number of complications. Direct perforation of the lung has been reported to occur in up to 25% of cases, this may lead to a bronchopleural fistula. Trauma to the thoracic duct at the posterosuperior mediastinum may result in the development of a chylothorax. Haemorrhagic pericardial effusion, causing cardiac tamponade has also been reported following chest drain insertion. Phrenic nerve injury is most likely to occur if the drain is placed deep in the chest where the phrenic nerve runs over the mediastinum (7,11,12). Because of its length, the phrenic nerve is very susceptible to trauma. The traumatic causes of diaphragm paralysis include open-heart surgery, lung transplantation, esophageal surgery (11,13). Also, is related to abnormal location of the medial end of the chest tube. In our patient, the most likely cause was direct phrenic nerve injury cause by the chest drain tip. Although it is suggested that on the frontal chest radiograph, the medial end of the chest tube should be no less than 1-2 cm from the spine, the chest tube was passing the midline in our patient.

Suspicion is the first step in diagnosis of diaphragm paralysis. Decreased respiratory sounds in auscultation and elevated hemidiaphragm on chest X-rays of patients, however, the confirmation requires diaphragm mobility tests by ultrasound and/or fluoroscopy during spontaneous breathing (6,13-15). Diaphragmatic ultrasound who useful in the diagnosis of unilateral diaphragmatic paralysis, showing thinner than normal diaphragms that fail to increase in thickness during contraction (16). Our patient's ultrasound investigation demonstrated absent movement with the infant during spontaneous breathing.

Most patients with unilateral diaphragmatic paralysis are asymptomatic and require no treatment.

However, in children under 1 year of age diaphragmatic plication has become a standard treatment for diaphragm paralysis (14). Our patient underwent a thoracotomy and plication of the left hemidiaphragm.

In conclusion, extravasation of parenteral alimentation fluid due to vascular erosion and diaphragma paralysis after chest drain insertion are rare complications, espe-

cially in neonates. With this case report, we want to emphasize that in sudden respiratory failure of a preterm baby with central catheter, TPN extravasation due to vascular erosion should be kept in mind. High attention should be paid especially in preterm infants with small size to preserve the function of phrenic nerve.

CONFLICT of INTEREST

None declared.

REFERENCES

- Ramasethu J. Complications of vascular catheters in the neonatal intensive care unit. *Clin Perinatol* 2008; 35: 199-222.
- Hermansen MC, Hermansen MG. Intravascular catheter complications in the neonatal intensive care unit. *Clin Perinatol* 2005; 32: 141-56.
- Lee EK. An unexpected left hydrothorax after left internal jugular venous catheterisation for total parental nutrition and antibiotics. *Annals Academy of Medicine* 2006; 35: 742-4.
- Walshe C, Phelan D, Bourke J, Buggy D. Vascular erosion by central venous catheters used for total parenteral nutrition. *Intensive Care Med* 2007; 33: 534-7.
- Pellaton C, Monti M, Fitting JW. Thoracentesis. *Rev Med Suisse* 2008; 4: 2319-23.
- Nahum E, Ben-Ari J, Schonfeld T, Horev G. Acute diaphragmatic paralysis caused by chest-tube trauma to phrenic nerve. *Pediatr Radiol* 2001; 31: 444-6.
- Odita JC, Khan AS, Dincsoy M, Kayyali M, Masoud A, Ammari A. Neonatal phrenic nerve paralysis resulting from intercostal drainage of pneumothorax. *Pediatr Radiol* 1992; 22: 379-81.
- Mukau L, Talamini M, Sitzmann J. Risk factors for central venous catheter-related vascular erosions. *J Parenter Enter Nutr* 1991; 15: 513-6.
- Valassiadou K, Prinianakis G, Sanidas E, Tsiftsis D, Georgopoulos D. Milky-white pleural effusion in a patient with acute respiratory failure: a case report. *Intensive Care Med* 2000; 26: 645-6.
- Di'azl M, Lorda I, Sa'nchez C, Gutierrez I, Monto'n JM, Vidal A. Milky-white pleural effusion complicating peripherically inserted central venous catheter for total parenteral nutrition. *Eur J Clin Nutr* 2005; 59: 302-3.
- Arya H, Williams J, Ponsford SN, Bissenden JG. Neonatal diaphragmatic paralysis caused by chest drains. *Arch Dis Child* 1991; 66: 441-2.
- Williams O, Greenough A, Mustfa N, Haugen S, Rafferty GR. Extubation failure due to phrenic nerve injury. *Arch Dis Child Fetal Neonatal* 2003; 88: 72-3.
- Qureshi A. Diaphragm paralysis. *Semin Respir Crit Care Med* 2009; 30: 315-20.
- Joho-Arreola AL, Bauersfeld U, Stauffer UG, Baenziger O, Bennet V. Incidence and treatment of diaphragmatic paralysis after cardiac surgery in children. *European Journal of Cardiothoracic Surgery* 2005; 27: 53-7.
- Akay TH, Ozkan S, Gultekin B, Uguz E, Varan B, Sezgin A, et al. Diaphragmatic paralysis after cardiac surgery in children: incidence, prognosis and surgical management. *Pediatr Surg Int* 2006; 22: 341-6.
- Gottesman E, McCool D. Ultrasound evaluation of the paralyzed diaphragm. *Am J Respir Crit Care Med* 1997; 155: 1570-4.